



WRIST

What's new in the treatment of distal radius fractures?

F. Lam^{a,*}, N. Jaysekera^b, S. Karmani^b, J.B. Jupiter^c

^aDepartment of Orthopedics, Eastbourne District General Hospital, Kings Drive, Eastbourne, East Sussex BN21 24D, UK

^bDepartment of Orthopedics, Mayday University Hospital, 530 London Road, Thornton Heath, Croydon CR7 7YE, UK

^cOrthopedic Associates, 55 Fruit Street, YAW 2162, Boston, MA 02114-2696, USA

KEYWORDS

Distal radius fractures;
Plates;
Fixation

Summary

The distal radius is the commonest site of fracture in the human skeleton and its treatment continues to evolve with advancing technology. Recently, there have been further refinements in the design of fixed-angle devices, pegs, locking plates and screws as well as arthroscopic instruments to assist management. In this article, we shall discuss the use of fixed-angle fixation devices, internal distraction plating, arthroscopically assisted reduction, fragment-specific fixation and the use of bone graft substitutes in the treatment of distal radius fractures.

© 2006 Elsevier Ltd. All rights reserved.

Evolution of distal radius plates

Since the introduction of the small fragment T plate by Mathys in 1973, there have been further refinements in the design of low-profile anatomically contoured plates, fixed-angle devices and pegs. Since most distal radius fractures are dorsally displaced, it seems rational for the fixation plate to be applied dorsally. The Pi plate (Synthes, Paoli, Pennsylvania) was one of the earlier designs of anatomically contoured plates specifically intended for dorsal fixation of the radius. However, despite its low contact design, there were problems with tendon irritation limiting its use. One study compared the results of Pi plate fixation with two quarter tubular plate fixation and found that the incidence

of extensor tenosynovitis was higher with the Pi plate and the range of wrist motion was also less compared with the quarter tubular plating group.¹

After this initial disappointment with dorsal plating, there was much interest in the use of volarly applied fixed-angle fixation devices for both dorsal and volar displaced fractures. These fixed-angle devices include fixed-angle blades, e.g. SCS plate (Subchondral Support plate, Avanta, San Diego, CA) which support the metaphyseal fragments and locking screws/pegs, e.g. DVR plate (Distal Volar Radius Plate, Hand Innovations, Miami, Florida).

The DVR plate has two rows of pegs, a proximal row supporting the dorsal aspect of the subchondral bone and a distal row supporting the central and volar aspect of the subchondral bone. The plate also extends over the volar margin of the lunate fossa providing a buttressing effect. Biomechanically, a volarly placed fixed-angle device may provide more stability than a dorsal one since the articular

*Corresponding author.

E-mail address: mrflam@hotmail.com (F. Lam).

margin of the distal radius normally has a volar inclination which displaces the joint reaction force closer to the volar plate, and thus decreasing the bending moment.²

Recently, there have been further refinements in the design of dorsal fixation using 2.4mm fragment-specific plates (AO/ASIF, Synthes, USA).³ There exists a radial column plate for fixation of the radial column and a T- or L-shaped plate for dorsal fixation of the intermediate column. Several modifications were made to reduce tendon irritation; these include polished surfaces with smooth tapered edges, precontouring of the plate thus reducing the need for cutting and bending and low-profile 2.4mm screws.

Internal distraction plating

Internal distraction plating of the distal radius involves the application of a dynamic compression plate from the radius to the middle-finger metacarpal bypassing the distal radius fracture site (Fig. 1). This technique is most useful in highly comminuted osteoporotic distal radial fractures involving the metaphyseal–diaphyseal junction. It may serve as an alternative to a bridging external fixator especially in elderly patients, avoiding the complications associated with external pins.

The surgical technique involves two and sometimes three incisions.⁴ The first incision is centred over the middle-finger metacarpal shaft. The second incision is placed over the dorsal aspect of the radial shaft at least 4cm from the

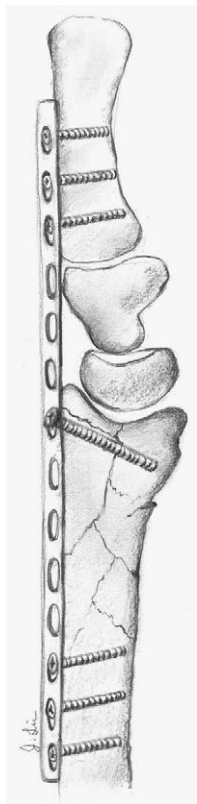


Figure 1 The distraction plate is applied to the middle-finger metacarpal and radial shaft with the wrist in neutral rotation.

fracture site. Sometimes, a third incision is required over Lister's tubercle to facilitate passage of the plate under the extensor tendons and to retract the extensor pollicis longus tendon. In situations where there is extensive metaphyseal bone loss, supplementary bone graft can also be inserted into the defect through this incision. After regaining radial length by manual traction, the plate is fixed to the bone with the wrist in neutral position. A lag screw can also be inserted through the plate if the intra-articular fragment is large enough.

In a series of 22 patients with a comminuted distal radial fracture treated with internal distraction plating, Ruch reported excellent results in 14 patients, good in six patients and fair in two.⁵ The average time to union was 110 days and the distraction plate was removed after fracture consolidation at an average of 124 days. Interestingly, there was no correlation between the duration of plate immobilisation and the range of wrist movements or functional scores at follow-up. The most common complication encountered was extensor lag of the middle finger (10%).

Fragment-specific fixation

The concept of fragment-specific fixation evolved as it became clear that the use of a single-sized plate cannot be used for fixation for all fracture configurations. Since the introduction of the '3 column concept' of the distal forearm by Rikli and Regazzone,⁶ a number of biomechanical studies have shown that rigid fixation of both the radial and intermediate columns is required for adequate stability, supporting radial inclination and radial tilt.⁷ The Trimed Wrist Fixation System (Trimed, Valencia, California) was introduced in 1996 by Medoff in Hawaii and consists of a highly versatile range of low-profile anatomically contoured plates, plate-supported pins (Fig. 2), wire forms and buttress wire forms (Fig. 3) to address each individual fracture fragment. The radial column is addressed with a radial plate, the dorsal intra-articular fragment fixed with a wire form, the dorsal ulnar fragment fixed with an ulnar pin plate and the volar articular fragment stabilised with an L plate.

The surgical technique typically involves a combination of volar and dorsal approaches.⁸ The volar Henry approach between flexor carpi radialis and radial artery is used to expose the volar aspect of the distal radius after subperiosteal elevation of pronator quadratus. To obtain access to the radial column, the extensor tendons of the first compartment will also need to be elevated subperiosteally. Dorsally, a standard approach over the third extensor compartment is used and the extensor pollicis longus tendon is released and retracted radially. Fracture reduction should begin only after both of these approaches have been carried out to evaluate the fracture configuration adequately. To address a volarly displaced fragment, a volar wire form can be used. The wire form is first pre-contoured to fit the shape of the volar cortex and later impacted into the bone after drilling two holes into the volar cortex. The fixation is secured after application of two washers and screws (Fig. 3).

The wire form can also be applied dorsally and in cases of a fracture involving the dorso-ulnar portion of the distal radius, an ulnar pin plate can be used which is ideal for small

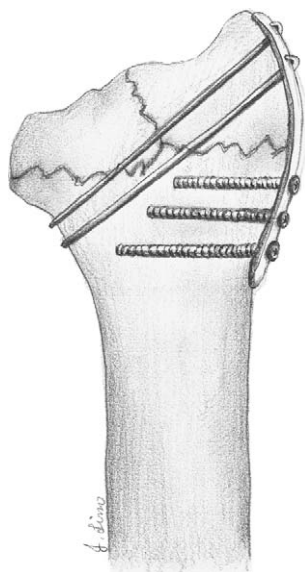


Figure 2 The radial pin plate can be used to stabilise the radial column by means of a combination of cortical screws proximally and K wires distally. The K wires are passed through the proximal pin holes of the plate into the distal fragment.

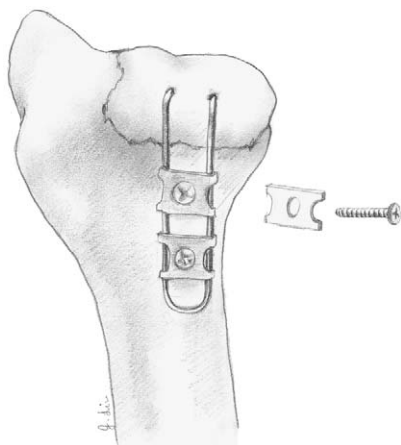


Figure 3 The volar pin plate is ideal for fixation of a displaced volar ulnar fragment. The volar wire form is prebent to fit the contour of the volar ulnar aspect of the radius and is secured with two screws and washers.

ulnar-sided corner fragments. The rationale of the pin plate is that it acts as a cortical buttress and also provides strong two-point K wire fixation of the small distal fragment (Fig. 2). The first point of fixation is achieved by the K wire penetrating through the far cortex of the proximal intact diaphysis and the second point of fixation is where the wire is supported by the plate. For the fixation of the radial column, there is a separate radial pin plate. There is also a buttress clip which is used for a central die punch fragment allowing elevation of the depressed fragment and supplementary bone graft if necessary.

Several investigators have reported encouraging results of fragment-specific fixation with over 85% of AO-type C2 and C3 fractures achieving good or excellent results.⁹ The main

advantage of this fixation technique is related to its superior biomechanical stability since each major fragment is stabilised, thus allowing early mobilisation without the need for additional immobilisation. The main complication is tendon irritation and rupture, with up to 23% of patients (21/92) requiring hardware removal subsequently.

Arthroscopically assisted fixation

In 1986, Knirk and Jupiter demonstrated that patients with an articular step off at the radiocarpal joint of more than 2mm were more likely to develop degenerative wrist disease.¹⁰ More recently, other investigators have found that the complication rate is significantly lowered if the articular incongruity is less than 1mm.¹¹ This level of accuracy is difficult to achieve using fluoroscopy alone and hence arthroscopy has been introduced as an adjunct to assist fracture reduction. This technique is particularly useful in 3-part and 4-part fractures with fragments greater than 1cm. Furthermore, arthroscopy can also detect carpal ligamentous injuries, distal radioulnar joint instability as well as osteochondral flaps and loose bodies. In a series of 60 patients with an intra-articular fracture of the distal radius, Geissler found during arthroscopy that 49% had a tear of the triangular fibrocartilage complex, 32% had injury to the scapholunate ligament and 15% had injury to the lunotriquetral ligament.¹²

The surgical technique is well described in several papers.^{13,14} Essentially, the conventional 3–4 portal between extensor pollicis longus and extensor digitorum communis tendons is used for visualisation. Irrigation of the joint is achieved through the 6U portal and the 6R portal is the main working portal where a shaver can be inserted to debride the joint improving visualisation. The ideal fracture configurations for arthroscopically assisted reduction are radial styloid fractures, die punch fractures, and 3-part and 4-part fractures. Generally, the radial styloid fragment is reduced first and stabilised with either K wires or cannulated screws. Sometimes, an additional K wire can be passed into the radial styloid fragment acting as a joystick to aid manipulation. Following this, the depressed lunate facet fragment is then elevated to the radial styloid fragment which acts as a landmark. The reduction is then stabilised with multiple K wires and the accuracy checked arthroscopically. Finally, the fixation is completed after application of the plate.

Several studies have demonstrated that arthroscopically assisted reduction and internal fixation yield better results with greater range of wrist motion than conventional open reduction and internal fixation.^{15–17} In addition, Ruch found that 10 of the 15 patients treated with arthroscopic reduction were found to have a tear of the triangular fibrocartilage complex, seven of which were peripheral and repaired acutely.¹⁷ This has important prognostic significance since treated acute tears do better than chronic ones. At final follow up, there were no cases of distal radio-ulnar joint instability in the arthroscopic group compared with 27% (4/12) in the closed reduction and external fixation group.

In recent years, there has been an increased awareness of the significance of ulnar-sided wrist injuries which have previously been underestimated. It is estimated that 20% of

patients after sustaining a distal radius fracture complain of persistent ulnar-sided wrist pain. Common reasons for this include malunion and consequent shortening of the radius leading to a relatively long ulna causing abutment, tear of the triangular fibrocartilage complex, distal radio-ulnar joint instability, distal radio-ulnar joint incongruity and non-union of hypertrophic ulnar styloid.¹⁸

Bone graft substitutes

In the past few years, there has been increasing interest in the use of bone graft substitutes in the treatment of distal radius fractures. Although autogenous bone graft has been traditionally regarded as the gold standard, its use is associated with significant donor site morbidity. Bone grafting is generally indicated in distal radius fractures: (1) for structural bone support, for example, if there is a significant bone defect particularly in osteoporotic bone, and (2) to augment healing in fracture non-union. The bone graft substitutes available include those based on naturally occurring materials such as demineralised allograft bone matrix, bovine collagen mineral composites, coralline hydroxyapatite and synthetic materials such as calcium sulphate pellets, bioactive glass, and calcium phosphate cement.

Norian SRS is an injectable paste consisting of monosodium phosphate, tricalcium phosphate, calcium carbonate and sodium phosphate. After excellent results were reported by an initial study,¹⁹ the use of Norian SRS was further supported by a prospective randomised study showing that patients treated with Norian SRS with or without adjuvant external fixation had significantly earlier return to function than the group treated with casting or percutaneous pin or external fixation alone.²⁰

The use of carbonated hydroxyapatite in distal radius corrective osteotomies was reported by Luchetti who found a 100% union rate with radiographic evidence of complete graft integration into the bone tissue.²¹ There was improvement in range of wrist motion, forearm rotation as well as grip strength.

With the increasing ageing of the population and a higher incidence of high-velocity trauma, the need for bone graft material is likely to expand. The future management of distal radius fractures is likely to be revolving around genetic engineering and refinements in internal fixation techniques.

References

- Hahnloser D, Platz A. Internal fixation of distal radius fractures with dorsal dislocation: pi plate or two 1/4 tube plates? A prospective randomized study. *J Trauma* 1999;47:760-5.
- Orbay J, Badia A, Khoury R, et al. Volar fixed angle fixation of distal radius fractures: the DVR plate. *Tech Hand Upper Extremity Surg* 2004;8(3):142-8.
- Tavakolian J, Jupiter JB. Dorsal plating for distal radius fractures. *Hand Clin* 2005;21:341-6.
- Papadonikolakis A, Ruch DS. Internal distraction plating of distal radius fractures. *Tech Hand Upper Extremity Surg* 2005;9(1):2-6.
- Ruch DS, Ginn TA, Yang CC, et al. Use of a distraction plate for distal radial fractures with metaphyseal and diaphyseal comminution. *J Bone Jt Surg (Am)* 2005;87(5):945-54.
- Rikli D, Regazzoni P. Fractures of the distal end of the radius treated by internal fixation and early function: a preliminary report of 20 cases. *J Bone Jt Surg* 1996;78B(4):588-92.
- Naidu SH, Capo JT, Moulton M, et al. Percutaneous pinning of distal radius fractures: a biomechanical study. *J Hand Surg (Am)* 1997;22:252-7.
- Schumer ED, Leslie BM. Fragment specific fixation of distal radius fractures using the Trimed device. *Tech Hand Upper Extremity Surg* 2005;9(2):74-83.
- Price JS, Korris M, Leslie B, et al. Initial outcome of distal radius fractures treated with the Trimed Wrist Fixation System. In: *Presented at the 56th Annual Meeting of the American Society for Surgery of the Hand*, Baltimore, MD, October 2001.
- Knirk JL, Jupiter JB. Intra-articular fractures of the distal end of the radius in young adults. *J Bone Jt Surg* 1986;68A:647-58.
- Fernandez DL, Geissler WB. Treatment of displaced articular fractures of the radius. *J Hand Surg (Am)* 1991;16A:375-84.
- Geissler WB, Freeland AE, Savoie FH, et al. Intra-articular soft tissue lesions associated with an intra-articular fracture of the distal end of the radius. *J Bone Jt Surg* 1996;78A:357-65.
- Guofen C, Doi K, Hattori Y, Kitajima I. Arthroscopically assisted reduction and immobilization of intra-articular fracture of the distal end of the radius: several options of reduction and immobilization. *Tech Hand Upper Extremity Surg* 2005;9(2):84-90.
- Geissler WB. Intra-articular distal radius fractures: the role of arthroscopy? *Hand Clin* 2005;21:407-16.
- Stewart NJ, Berger RA. Comparison study of arthroscopic and open reduction of comminuted distal radius fractures. In: *Presented at the 53rd Annual Meeting of the American Society for Surgery of the Hand [programs and abstracts]*. January 11, 1998, Scottsdale, AZ.
- Doi K, Hattori T, Otsuka K, Abe T, Tamamoto H. Intra-articular fractures of the distal aspect of the radius arthroscopically assisted reduction compared with open reduction and internal fixation. *J Bone Jt Surg* 1999;81A:1093-110.
- Ruch DS, Vallee J, Poehling GG, Smith BP, Kuzma GR. Arthroscopic reduction versus fluoroscopic reduction of intra-articular distal radius fractures. *Arthroscopy* 2004;20:225-30.
- Lindau T. Treatment of injuries to the ulnar side of the wrist occurring with distal radial fractures. *Hand Clin* 2005:417-25.
- Jupiter JB, Winters S, Sigman S, et al. Repair of five distal radius fractures with an investigational cancellous bone cement: a preliminary report. *J Orthop Trauma* 1997;11:110-6.
- Ladd AL, Pliam NB. Use of bone graft substitute in distal radius fractures. *J Am Acad Orthop Surg* 1999;7:279-90.
- Luchetti R. Corrective osteotomy of malunited distal radius fractures using carbonated hydroxyapatite as an alternative to autogenous bone grafting. *J Hand Surg [Am]* 2004;29(5):825-34.